

Evaluation of a Cyanoacrylate Protectant* to Manage Peristomal Skin Irritation under Ostomy Skin Barrier Wafers

Catherine T. Milne, MSN, APRN, CWOCN¹
Darlene Saucier, MSN, APRN, CWCN¹
Chenel Trevellini, BSN, CWOCN²
Juliet Smith RN, MSN, CWON³

¹Connecticut Clinical Nursing Associates, LLC

Bristol Hospital Wound, Ostomy, Lymphedema Center, Bristol, CT


²St. Francis Hospital/Catholic Health System Long Island, Roslyn, NY

³NY Presbyterian Hospital/Columbia University Medical Center, New York, NY

Study # LIT236R

This study was sponsored by:

Educare[™]
wound & skin care education

The clinical education division of 

©2010 Medline Industries, Inc. One Medline Place, Mundelein, IL 60060
Medline and Educare are registered trademarks of Medline Industries, Inc.
1-800-MEDLINE (1-800-633-5463) www.medline.com

MKT210344/LIT236R/2.5M/K&M7

Evaluation of a Cyanoacrylate Protectant* to Manage Peristomal Skin Irritation under Ostomy Skin Barrier Wafers

INTRODUCTION

Peristomal irritation in ostomy patients is a common occurrence^{1,2,3}, and it has been reported that 10 to 70% of ostomy patients experience some type of peristomal skin problems.^{4,7} Mechanical, chemical, and microbial causes are implicated in these skin complications. These skin conditions can range from an abrasion or skin stripping to full thickness wounds that make it extremely difficult to manage the stoma with any degree of comfort.

Leakage of urine, undigested food matter, and feces are the major cause peristomal skin irritation.² In patients with an ileostomy, where the stool has not yet been processed by the large bowel, the effluent tends to contain high levels of proteolytic digestive enzymes and has a high alkalinity. These ingredients are known to cause significant damage to skin. Another very common cause of skin irritation is an ill-fitting appliance, whose use may be accompanied with frequent mechanical stripping by the wafer adhesive.^{5,6} Moisture associated skin irritation due to leakage adds to the damage potential on sensitive peristomal skin.⁷ Microbial complication of the peristomal skin can add to loss in the epidermal integrity.⁷

MANAGEMENT OF PERISTOMAL SKIN IRRITATION

Prompt management of affected peristomal skin leads to improvement in ostomy barrier wafer efficiency and patient comfort, both of which significantly upgrade the quality of life. Early intervention of strategies to protect peristomal skin irritation is paramount to avoid complications which may include full thickness tissue loss.

Traditionally, several choices have been available to the clinician and caregiver to manage the patient with peristomal skin irritation.¹ Liquid skin barriers, preferably the no-sting variety, can be utilized to create a dry platform on which a pouch can be attached with some degree of confidence. Stoma powders and calamine lotion have also been used to dry the peristomal skin. Individualized wafer selection suited for the patient's anatomy and stoma shape is always mandated.

CLINICAL PROBLEM

Peristomal skin irritation, under ostomy wafers is a commonly reported problem.^{1,2} Peristomal skin irritation often results in severe erosion, bleeding, discomfort and increased healthcare costs related to supply use and provider visits. Of reported interventions,¹ the use of cyanoacrylate to manage skin irritation has received little attention as a viable option.

METHODS

Using a convenience sample, a topical cyanoacrylate dressing was applied to eleven patients with peristomal skin irritation under their ostomy wafers in acute care and outpatient settings. Patients or nursing staff were instructed to apply a cyanoacrylate topical protectant to the peristomal skin at each wafer change. Patients were assessed for wound discomfort using a Likert Scale, time to closure and number of appliance changes. Patient satisfaction was also examined.

RESULTS

Average reported discomfort levels of 9.5 out of 10 at the initial peristomal skin irritation assessment visit decreased to 3.5 at the first wafer change and were absent by the second wafer change. Wafers had increasing length between changes in both settings with acute care patients responding faster. Epidermal resurfacing occurred within 10.2 days in outpatients and within 7 days in acute care patients. Because of the skin sealant action of this dressing, immediate adherence of the wafer was reported at all wafer changes. Patients reported high satisfaction with this method of peristomal skin irritation management due to reduced discomfort and immediate wafer adherence.

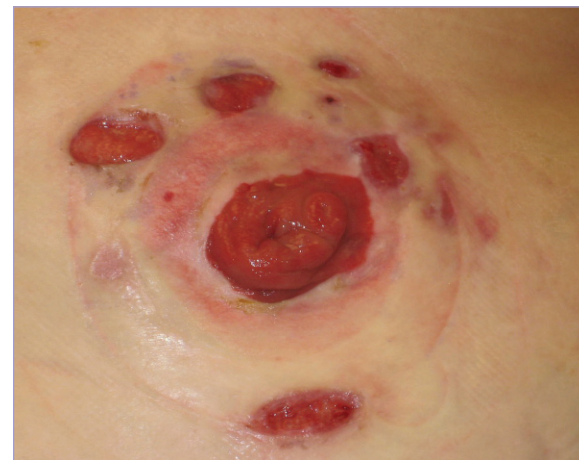CONCLUSION

The use of cyanoacrylate dressings is a viable option to manage peristomal skin irritation under ostomy wafers in both acute and long-term care settings. Further study on a large scale basis is warranted.

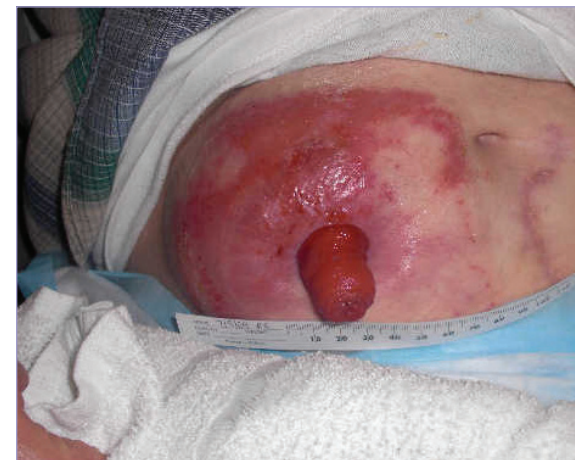REFERENCES

1. Rolstad B, Erwin-Toth P. Peristomal skin complications: Prevention and Management. *Ostomy Wound Management*. 2004;50(9):68-77.
2. Ratliff CR, Scarano KA, Donovan AM, Colwell JC. Descriptive study of peristomal complications. *JWOCN* 2005;32(1):33-7.
3. Herlufsen P, Olsen AG, Carlsen B, et al. Study of peristomal skin disorders in patients with permanent stomas. *Br J Nurs*. 2006;15(16):854-862.
4. Colwell J, Goldberg M, Carmel J. The state of the standard diversion. *JWOCN*. 2001;28:6-17.
5. Erwin-Toth P. Prevention and management of peristomal skin complications. *Adv Skin Wound Care*. 2001;14:1-6.
6. Lyon CC, Smith AJ, Griffiths CEM, Beck MH. The spectrum of skin disorders in abdominal stoma patients. *Br J Dermatol*. 2000;143(6):1248-1260.
7. Ratliff CR, Donovan AM. Frequency of peristomal complications. *OWM*. 2001;47:26-29.

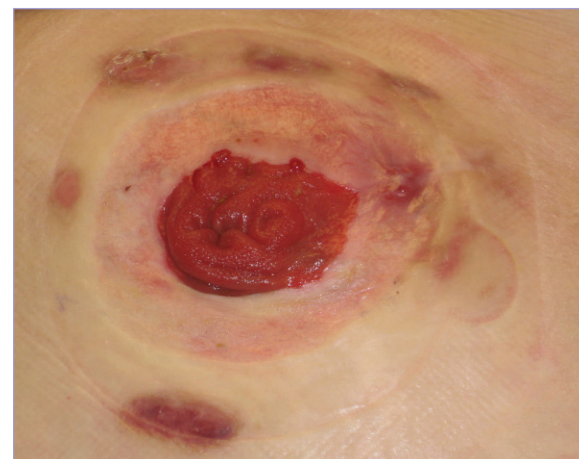
Patient A - before cyanoacrylate



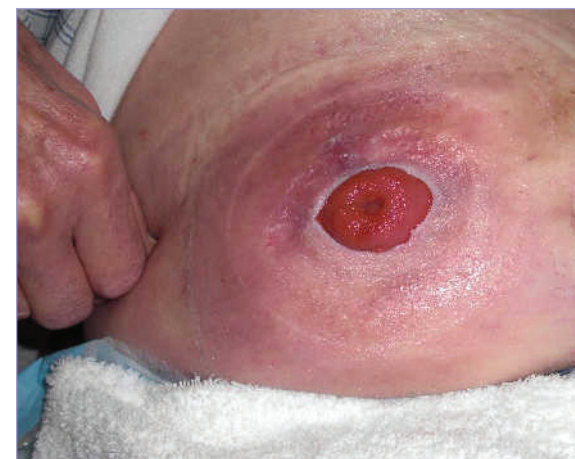Patient B - before cyanoacrylate



Patient A - after cyanoacrylate



Patient B - after cyanoacrylate



application of the cyanoacrylate

